

A Rare Cause of Orbital Compartment Syndrome: Gunshot Injury

Önder Yeşiloğlu

Gaziantep 25 Aralık State Hospital, Clinic of Emergency Medicine, Gaziantep, Turkey

Abstract

To our knowledge, there are no reported orbital compartment syndrome (OCS) cases caused by a foreign body in the orbit accompanying retrobulbar bleeding after gunshot injury. A 44-year-old male patient presented to our emergency room with a gunshot injury, stating that a bullet hit his right eye approximately 20 min before the visit. A single bullet entry hole was visible on the lateral side of his right lower eyelid. Proptosis, ecchymosis, edema, conjunctival chemosis and lateral strabismus was present in the patient's right eye. The tonicity of the right eye was slightly increased on palpation and the patient was considered to have OCS. Computed tomography (CT) was performed, which revealed retrobulbar hemorrhage and a bullet fragment stuck in the orbital posterior wall. Anti-edema treatment was initiated and lateral canthotomy/cantholysis was planned for the patient. Another orbital CT showed perforation in the injured eye. The patient was re-evaluated by ophthalmology and neurosurgery specialists, and the foreign body (bullet nucleus) in the retrobulbar region was removed by neurosurgery specialist. The patient was discharged with recommendations from the neurosurgery ward after 5 days. OCS can occur as a rare complication of a gunshot injury. Eye tonicity of patients with firearm injuries to the ocular area should be evaluated at frequent intervals and the need for cantotomy or cantolysis should be considered with a multidisciplinary approach in this setting.

Keywords: Orbital compartment syndrome, emergency, gunshot, neurosurgery and ophthalmology

Introduction

Orbital compartment syndrome (OCS) is an important ophthalmological emergency that can result in permanent vision loss unless corrected [1]. Permanent vision loss depends on the severity and location of the increased pressure and may be caused by the direct compression of neurovascular structures or disruption of the perfusion membrane due to pressure [2]. Multiple studies have shown permanent vision loss within the first 60-100 min unless corrected [2,3]. Because of the high risk and early development of this complication, imaging should be postponed and diagnosis should be based on the history and physical examination of the patient primarily, to prevent any delays. Lateral canthotomy/cantholysis (LC/C) is the preferred modality for the immediate treatment of OCS and has been recommended since the early 1990s [4]. OCS is rarely seen after facial or orbital trauma, and its most common cause is traumatic retrobulbar bleeding [5]. Here we present a case with penetrating orbital trauma as a rare cause of OCS.

Case Report

A 44-year-old male patient presented to our emergency room with a gunshot injury. He stated that the bullet hit his right eye approximately 20 min before the visit. Physical examination revealed a Glasgow Coma scale score of 15 at the time of admission. His vital signs were as follows: blood pressure, 130/80 mmHg; respiration rate, 14/minute; and oxygen saturation with a pulse oximeter, 95% (in room air). A bullet entry hole was detected on the lateral side of his right lower eyelid. Proptosis, ecchymosis, edema, conjunctival chemosis and lateral strabismus was present in the patient's right eye. Pupillary light and accommodation reflexes were absent. The tonicity of the right eye was slightly increased on palpation. There was no hyphaema or hypopyon. The patient's visual acuity was decreased at a distance of 1 meter. Based on these findings, the patient was considered to have OCS. His intraocular pressure (IOP) was measured to be 55 mmHg using a tonometer. The first orbital computed tomography (CT) revealed retrobulbar hemorrhage and a bullet fragment stuck in the



Address for Correspondence: Önder Yeşiloğlu MD, Gaziantep 25 Aralık State Hospital, Clinic of Emergency Medicine, Gaziantep, Turkey
Phone: +90 507 587 91 41 **E-mail:** dronderyesiloglu@gmail.com **ORCID-ID:** orcid.org/0000-0003-0149-8456
Received: 21.03.2022 **Accepted:** 24.05.2022

© Copyright 2022 by the Turkish Emergency Medicine Foundation, Global Emergency and Critical Care published by Galenos Publishing House.

orbital posterior wall (Figure 1), pressing the optic nerve (Figure 2). The patient's eyeball was protected. Immediately after that, LC/C was planned for the patient. Anti-edema treatment with a combination of 20% intravenous mannitol (2 g/kg) and methylprednisolone (250 mg) was initiated as adjuvant treatment before the surgery. The patient was consulted by neurosurgery and ophthalmology specialists. Physical examination was repeated after 15 min, while the medication was continued. Re-examination revealed a reduction in the

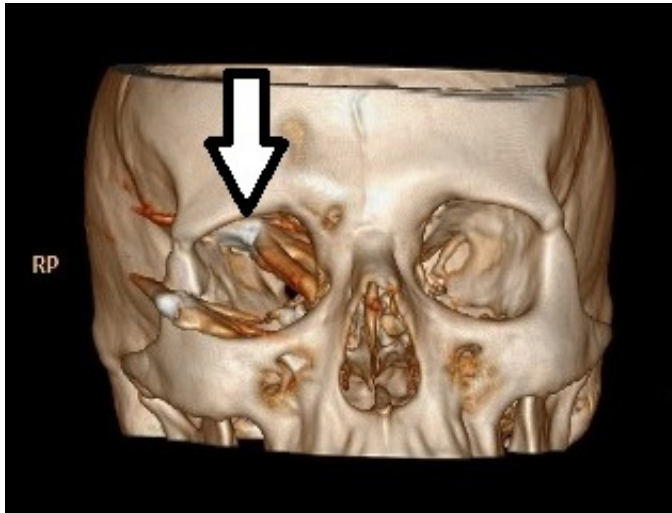


Figure 1. Three-dimensional orbital computed tomography of the patient. The arrow shows the bullet core (arrow)

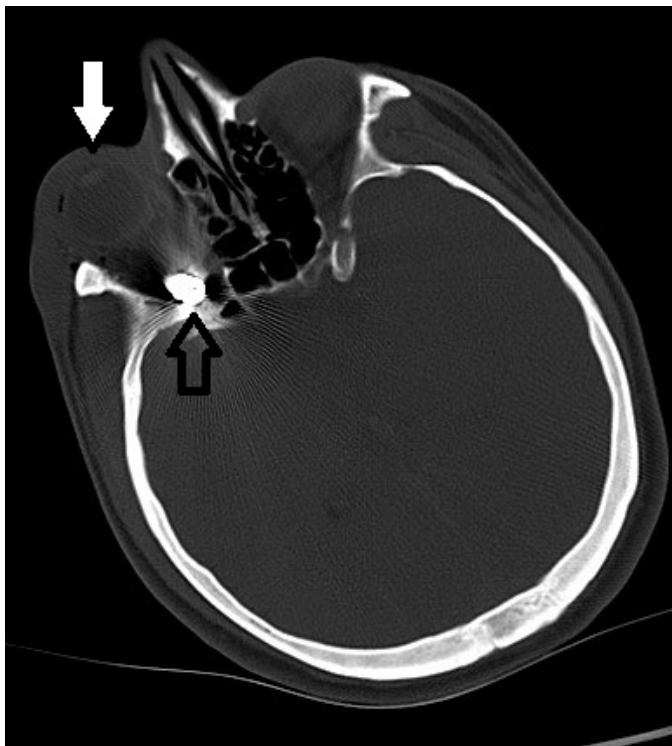


Figure 2. The bullet nucleus is seen in the retro-orbital region (black arrow). The eyeball boundaries are seen normally (white arrow) on orbital computed tomography

tonicity of the injured eye. Another orbital CT was performed immediately, which showed perforation in the injured eye. The patient was re-evaluated by ophthalmology and neurosurgery specialists, and the foreign body (bullet nucleus) in the retrobulbar region was removed by neurosurgery. The patient was discharged with recommendations from the neurosurgery ward after 5 days.

Discussion

OCS is a rare complication caused by an increase in the volume and pressure of the orbital cavity. It is a serious ophthalmological emergency, requiring urgent intervention [1,2]. The most common cause of OCS is retrobulbar hemorrhage secondary to blunt trauma to the orbital cavity or subperiosteal space [6], as IOP rarely increases after penetrating trauma to the eye [2,6]. To our knowledge, there is no reported case of OCS caused by a foreign body in the orbit accompanying retrobulbar bleeding after a gunshot injury.

The normal orbital volume is approximately 30 mL, and the normal IOP is lower than 20 mmHg (usually around 3-6 mmHg) [7]. Increases in the orbital pressure and volume can be compensated with proptosis to some degree; however, lateral and medial canthal ligaments limit this proptosis to an extent. The diagnosis of OCS is usually based on the patient history and clinical findings and does not require radiological imaging. Decreased visual acuity in the affected eye, proptosis, subconjunctival hemorrhage accompanying edema of the eyelid, ecchymosis, conjunctival chemosis, lateral strabismus and increased eye pressure (IOP >40 mmHg) with fixed enlarged pupils or an afferent pupillary defect is usually sufficient for the diagnosis of OCS after orbital and/or facial trauma [2]. All these symptoms were present in our patient.

As the intraorbital pressure exceeds the pressures of the central retinal and ophthalmic arteries, the blood flow in these vessels stops. Increased intraorbital pressure that lasts longer than 60-100 min have been shown to worsen ischemia and cause permanent vision loss. Therefore, if IOP becomes higher than 40 mmHg, LC/C should be urgently performed within the first 60-100 min [7]. In this study, IOP was measured in about 20 min and was found to be 55 mmHg, suggesting an increase in the orbital pressure due to the mass effect in the retrobulbar region by the foreign body. The decrease in the visual acuity of our patient was also thought to be caused by OCS and the bullet fragment stuck to the optic nerve.

After the diagnosis of OCS, an emergency LC/C was planned in our patient, which is the primary approach that commonly used to reduce orbital pressure [8]. The main indications for LC/C are decreased visual acuity, proptosis and IOP >40 mmHg. IOP >40 mmHg is sufficient for performing LC/C if the patient is unconscious. In addition to surgical treatment,

osmotic agents (20% mannitol, 2 g/kg) and high-dose steroids (methylprednisolone, 250 mg) can be used to suppress post-traumatic inflammation and edema [9]. In this study, initial physical examination and imaging results suggested the presence of OCS during the first examination, and emergency decompression was initially planned; however, while re-evaluating the patient, palpation of the eye revealed decreased tonicity of the injured eyeball. Therefore, another CT scan was performed, which showed perforation in the affected eye. Standard treatment methods (e.g., LC/C) were abandoned because they were contraindicated in the presence of perforation [10]. While emergency LC/C is an effective method for the treating of OCS after blunt trauma, the indications for this treatment should be re-evaluated multiple times in patients with firearm injuries with high probability of eyeball perforation. Perforation should be considered if a sudden decrease in eye tonicity is detected on repeated physical examinations. As the measurement using a tonometer is contraindicated in the presence of perforation, diagnostic imaging studies (such as orbital CT) should be repeated in the early period to detect a possible perforation [11]. We believe the necessity of a multidisciplinary approach to decide the evaluation and decompression method in patients with OCS after a firearm injury.

Conclusion

OCS can occur as a rare complication of a gunshot injury. Unlike standard emergency decompression procedures performed in patients with OCS after blunt trauma, the preferred surgical decompression method in patients with a penetrating injury should be selected by performing an eye tonicity examination at frequent intervals. The possibility of perforation should be considered if the eye tonicity is decreased, and the appropriate surgical method should be determined by a multidisciplinary approach in such patients.

Ethics

Informed Consent: Verbal informed consent was obtained from the patient(s) for their anonymized information to be published in this case report.

Peer-review: Externally peer-reviewed.

Financial Disclosure: The author declared that this study received no financial support.

References

1. Tarff A, Behrens A. Ocular emergencies: red eye. *Med Clin North Am.* 2017;101:615-39.
2. Lima V, Burt B, Leibovitch I, Prabhakaran V, Goldberg RA, Selva D. Orbital compartment syndrome: the ophthalmic surgical emergency. *Surv Ophthalmol.* 2009;54:441-9.
3. Oester AE Jr, Fowler BT, Fleming JC. Inferior orbital septum release compared with lateral canthotomy and cantholysis in the management of orbital compartment syndrome. *Ophthalmic Plast Reconstr Surg.* 2012;28:40-3.
4. Vassallo S, Hartstein M, Howard D, Stetz J. Traumatic retrobulbar hemorrhage: emergent decompression by lateral canthotomy and cantholysis. *J Emerg Med.* 2002;22:251-6.
5. Ansari MH. Blindness after facial fractures: a 19-year retrospective study. *J Oral Maxillofac Surg.* 2005;63:229-37.
6. Edmunds MR, Haridas AS, Morris DS, Jamalapuram K. Management of acute retrobulbar haemorrhage: a survey of non-ophthalmic emergency department physicians. *Emerg Med J.* 2019;36:245-7.
7. Cheung CA, Rogers-Martel M, Golas L, Chepurny A, Martel JB, Martel JR. Hospital-based ocular emergencies: epidemiology, treatment, and visual outcomes. *Am J Emerg Med.* 2014;32:221-4.
8. Fox A, Janson B, Stiff H, Chung A, Benage M, Van Heukelom J, et al. A multidisciplinary educational curriculum for the management of orbital compartment syndrome. *Am J Emerg Med.* 2020;38:1278-80.
9. McCallum E, Keren S, Lapira M, Norris JH. Orbital compartment syndrome: an update with review of the literature. *Clin Ophthalmol.* 2019;13:2189-94.
10. McInnes G, Howes DW. Lateral canthotomy and cantholysis: a simple, vision-saving procedure. *CJEM.* 2002;4:49-52.
11. Bader J, Havens SJ. Tonometry. 2021 Aug 11. In: StatPearls [Internet]. Treasure Island (FL): StatPearls Publishing; 2022.