

A Mortal Case of Meningeal Tuberculoma with Isoniazid-induced Encephalopathy

© Mücahit Kesgün¹, © Gürkan Akman²

¹Dağkapı State Hospital, Clinic of Emergency Medicine, Diyarbakır, Turkey

²University of Health Sciences Turkey, Kartal Dr. Lütüfi Kırdar City Hospital, Clinic of Emergency Medicine, İstanbul, Turkey

Abstract

Tuberculosis continues to be a major cause of morbidity and mortality in low-income and middle income countries. The treatment of this disease also has different types of side effects. In this case report we discussed an unique and unknown cause of encephalopathy during treatment that induced by the use of isoniazid. There have reported cases of encephalopathy during drug treatment, while the reported case of isoniazid use is almost non-existent. The result of this condition can be as mortal as in this study. Because of that knowing its surgical and medical indications can have benefits to the survey. In this case report, our main aim is to describe these. During the management of cerebral tuberculoma patients, drug induced encephalopathy should be considered a mortal cause. When encephalopathy occurs during tuberculosis treatment, it should be kept in mind that this may occur secondary to isoniazid.

Keywords: Tuberculosis, isoniazid, mortality, tuberculoma

Introduction

Tuberculosis is a multi-systemic infectious disease caused by species of mycobacteria. Tuberculosis affects the central nervous system (CNS) in three different ways: tuberculous meningitis, meningeal tuberculoma and spinal tuberculous arachnoiditis. All three forms are common where tuberculosis incidence is high [1-3]. Among the CNS tuberculosis, the most urgent one is meningitis, while the most rare form is cerebral tuberculoma. Tuberculomas usually present with focal neurological findings. Therefore, it deserves new diagnostic methods, as in other pathologies [4,5]. They may be confused with malignant lesions, sarcoidosis, pyogenic abscesses, toxoplasmosis and cysticercosis [6].

The use of anti-tuberculosis drugs for treating this disease is the standard treatment. The response is generally good following anti-tuberculosis treatment and the prognosis is good after long-term treatment. In the treatment, isoniazid rifampicin is usually used for 4 months after 2 months of treatment with isoniazid pyrazinamide ethambutol rifampicin. Generally, no mortality

is observed for treating cerebral tuberculoma [7]. Of the anti-tuberculosis drugs used for treating cerebral tuberculoma, only isoniazid-induced encephalopathy and cerebral edema have been noted [8]. Rifampicin ethambutol and pyrazinamide-induced cerebral edema or encephalopathy have not been reported in the literature. In this article, isoniazid-induced encephalopathy that developed during the treatment of cerebral tuberculoma and causes mortality, is discussed.

Case Report

A 55-year-old male patient was brought to the emergency department by his relatives with the complaint of strange behavior. He had no chronic disease. The other neurological and systemic examinations of the patient with impaired orientation to place and time on the admission examination were normal. Initial laboratory values were white blood cell: 12.200; hemoglobin: 14.3. Serum creatinine, blood urea nitrogen, sodium, potassium, glucose, calcium, aspartate transaminase and alanine transaminase were normal. C-reactive protein was 3.72, which was increased (normal range: 0-0.08). Erythrocyte



Address for Correspondence: Mücahit Kesgün PhD, Dağkapı State Hospital, Clinic of Emergency Medicine, Diyarbakır, Turkey
Phone: +90 546 742 72 97 **E-mail:** mucahitkesgun@gmail.com **ORCID-ID:** orcid.org/0000-0003-3440-0267

Received: 19.03.2022 **Accepted:** 25.03.2022

© Copyright 2022 by the Turkish Emergency Medicine Foundation, Global Emergency and Critical Care published by Galenos Publishing House.

sedimentation rate was 28 mm/h and procalcitonin levels were in normal ranges. Multiple diffuse dense lesions were present in the bilateral cerebellum on the cranial computed tomography (CT). The IV contrast-enhanced cranial magnetic resonance imaging (MRI) of the patient showed multiple lesions with hypointense center and hyperintense periphery and no peripheral edema in the T2A sequence and with peripheral contrast uptake in the form of a ring after the administration of IV contrast agent (Figures 1, 2). The findings were evaluated in favor of multiple tubercular the patient was hospitalized in the infectious diseases service. A lumbar puncture of the patient revealed no evidence of meningitis. Patient's glucose was 97/185 and cerebrospinal fluid protein was 8.6. Toxoplasma immunoglobulin G and immunoglobulin M were negative. Venereal disease research laboratory test was negative. Anti-C was negative. No acid-resistant bacteria were seen in the acid resistant bacillus and no cavitory lesion was noted on the thorax CT. The patient with anergic purified protein derivative and positive T-spot test was initiated.

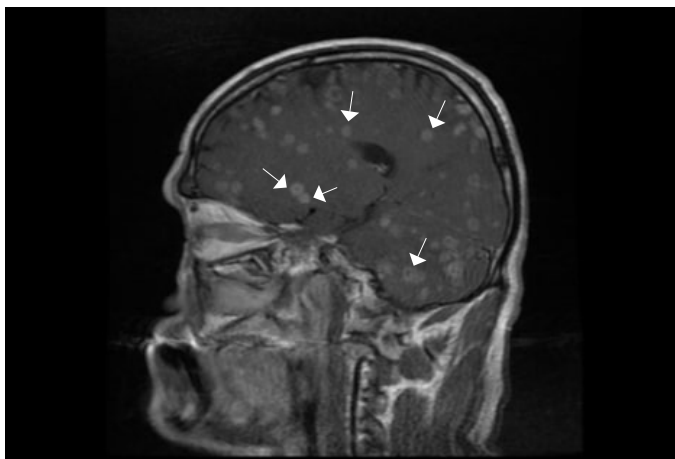


Figure 1. Intravenous contrast-enhanced cranial magnetic resonance imaging of the patient showed sagittal plane (white arrows)

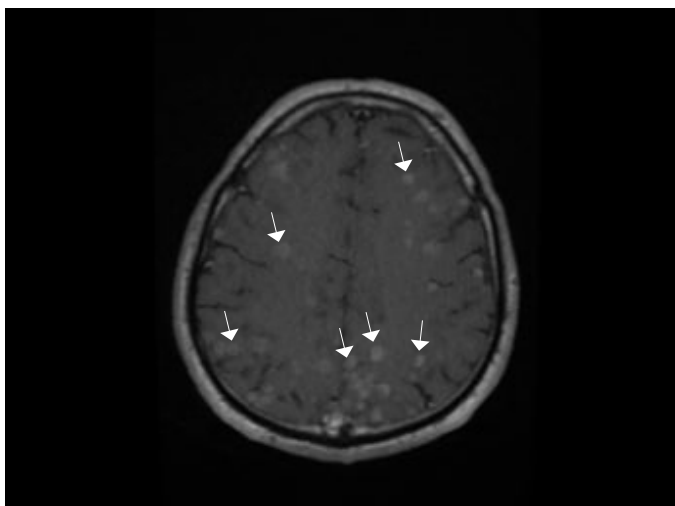


Figure 2. Intravenous contrast-enhanced cranial magnetic resonance imaging of the patient showed transverse plane (white arrows)

Treatment with isoniazid 300 mg, RIF 600 mg, ETM 1000 mg, PRZ 1500 mg and dexamethasone 3*8 mg was started. patient was scheduled for CT-guided biopsy. Biopsy could not be performed since the lesions visualized on MRI could not be distinguished clearly on CT. His neck ultrasonography showed a few reactive lymph nodes located in the left supraclavicular region, the largest of which was 4 mm in diameter. The patient had a severe headache and vomiting on the tenth day of admission. The cranial CT performed on the 10th day of the treatment revealed hydrocephalus. The patient underwent external ventricular drainage surgery. Somnolence and headache complaints persisted after the surgical intervention. On the 16th day of follow-up, the patient died from respiratory distress.

Discussion

Although tuberculosis is a common disease in developing countries, it is an infectious disease caused by mycobacterium tuberculosis, which continues to threaten public health in developed countries due to HIV epidemic and migration [2]. In 1993, the world health organization declared tuberculosis as a global emergency [9]. It is estimated that more than 1.7 billion people worldwide are affected by *tubercle bacillus* [10]. Although the incidence of tuberculosis tends to decline with strict policies implemented, it has not yet reached the desired level. Factors such as low socioeconomic status and access to quality healthcare are important challenges in tuberculosis control [11]. Additionally, drug resistance complicates the treatment [11].

In about 5%-10% of tuberculosis cases, CNS involvement is seen and it may show up as meningitis, solitary tuberculoma, abscess, infarction, or military parenchymal disease. Tuberculomas that may cause neurological findings due to local compression are less common [12].

It has also been reported that clinical tuberculomas may present with symptomatic intracranial mass lesions in regions with a high prevalence of tuberculosis. The usual patients are children or young adults who present with headache, seizure, focal neurological deficits, increased intracranial pressure symptoms [7]. Systemic disease symptoms and meningeal inflammation findings are usually absent [7]. It is usually diagnosed by clinical epidemiological and radiographic data or by needle biopsy. The surgical indications other than diagnosing these lesions are the critical location of the lesion, obstructive hydrocephalus, and brain stem compression [7]. In this study, hydrocephalus was observed on tomography performed on the 10th day.

Tuberculomas usually respond well to anti-tuberculosis treatment. Generally, meningeal tuberculoma cases have a good survival. In our case, the patient developed mortality

on the 16th day after the initiation of anti-tuberculosis treatment. Mortality in this case could not be attributed to a mass effect associated tuberculous tuberculomas. There are also no additional comorbidities that may cause mortality in the patient. Of the anti-tuberculosis drugs used for treating cerebral tuberculoma, only isoniazid-induced encephalopathy and cerebral edema have been noted in previous studies. Rifampicin ethambutol and pyrazinamide-induced cerebral edema or encephalopathy have not been reported in the literature. Cerebral edema and encephalopathy developed in the patient was associated with isoniazid. Isoniazid-induced encephalopathy and cerebral edema have been reported by a small number of studies.

Conclusion

It should be known that patient management with isoniazid may cause an isoniazid-induced encephalopathy and mortality in cerebral tuberculoma treatments.

Ethics

Informed Consent: Informed consent was obtained from the patient.

Peer-review: Externally peer-reviewed.

Authorship Contributions

Surgical and Medical Practices: M.K., Concept: G.A., M.K., Design: G.A., Data Collection or Processing: M.K., G.A., Analysis or Interpretation: M.K., G.A., Literature Search: M.K., G.A., Writing: M.K., G.A.

Conflict of Interest: No conflict of interest was declared by the authors.

Financial Disclosure: The authors declared that this study received no financial support.

References

1. Bahemuka M, Murungi JH. Tuberculosis of the nervous system. A clinical, radiological and pathological study of 39 consecutive cases in Riyadh, Saudi Arabia. *J Neurol Sci.* 1989;90:67-76.
2. Bourgi K, Fiske C, Sterling TR. Tuberculosis meningitis. *Curr Infect Dis Rep.* 2017;19:39.
3. al-Deeb SM, Yaqub BA, Sharif HS, Motaery KR. Neurotuberculosis: a review. *Clin Neurol Neurosurg.* 1992;94 Suppl:S30-3.
4. Alper B, Erdogan B, Erdogan MÖ, Bozan K, Can M. Associations of trauma severity with mean platelet volume and levels of systemic inflammatory markers (IL1 β , IL6, TNF α , and CRP). *Mediators Inflamm.* 2016;2016:9894716.
5. Colak S, Erdogan MO, Sekban H, Afacan MA, Uras AR, Ibrahim A, et al. Emergency diagnosis of upper gastrointestinal bleeding by detection of haemoglobin in nasogastric aspirate. *J Int Med Res.* 2013;41:1825-9.
6. Monteiro R, Carneiro JC, Costa C, Duarte R. Cerebral tuberculomas - a clinical challenge. *Respir Med Case Rep.* 2013;9:34-7.
7. Zunt JR. Tuberculosis of the central nervous system. *Continuum (Minneapolis).* 2018;24:1422-38.
8. Blakemore WF, Palmer AC, Noel PR. Ultrastructural changes in isoniazid-induced brain oedema in the dog. *J Neurocytol.* 1972;1:263-78.
9. Grange JM, Zumla A. The global emergency of tuberculosis: what is the cause? *J R Soc Promot Health.* 2002;122:78-81.
10. Houben RM, Dodd PJ. The global burden of latent tuberculosis infection: a re-estimation using mathematical modelling. *PLoS Med.* 2016;13:e1002152.
11. Elbek O. Ethical Issues in Tuberculosis Control. *Turk Thorac J.* 2015;16:73-85.
12. Sumer S, Koktekir E, Demir NA, Akdemir G. Intracranial giant tuberculoma mimicking brain tumor: a case report. *Turk Neurosurg.* 2015;25:337-9.